

Fall 2010

3 Tesla MRI Delivered

On Saturday October 09, 2010 Main Street Radiology III, located in downtown Flushing, accepted delivery of the Siemens 3T Magnetom open bore MRI. We are scheduled to see our first patient on October 20.

The Siemens 3T Magnetom Verio, which joins the 3T at our office located on Francis Lewis, is the world's first Open Bore 3T MRI.

Main Street Radiology III will now offer one of the most advanced MR imaging services with a magnet that is designed for maximum patient comfort. The Verio offers excellent image quality, superb diagnostic capabilities, and exceptional patient comfort with a large, patient friendly 70cm opening. The Verio boasts the strongest magnet field strength used clinically today and gives Main Street Radiology radiologists access to many applications, including neurology, orthopedic and cartilage assessment, and breast, vascular imaging.

HOUSECALLS Patient Appointment Notification System Implemented

Main Street Radiology is proud to announce that in September they purchased and installed the Televox Housecalls appointment reminder system.

The system notifies a patient 1-2 days in advance of their imaging appointments at Main Street Radiology through their home or cell phone number.

We have implemented the system because we feel it important to provide a high level of service with an efficient means of communication.

We are looking forward to you sharing any feedback you might receive from your patients

ELECTRONIC DELIVERY OF RADIOLOGY REPORTS

Main Street Radiology has a number of ways of delivering patient reports. Included are *MAIL, FAX, E-MAIL, And DIRECT TRANSMISSION*

If you are interested in changing the way your reports are transmitted to your office please contact Samantha Abreu at 718-428-1500 Ext 272

BREAST IMAGING DINNER LECTURE

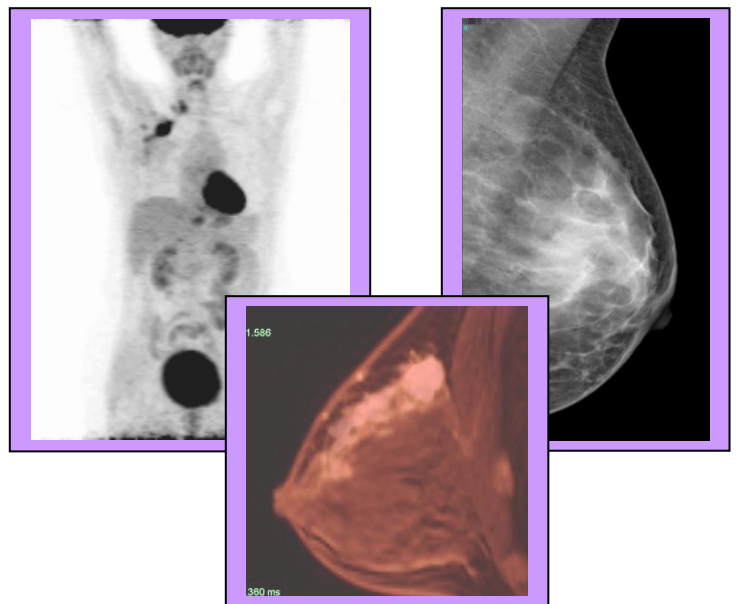
On Wednesday October 20, Main Street Radiology will present "**Updates in Breast Imaging**" at Burton & Doyle Restaurant.

The lecture will concentrate on three new imaging modalities in Breast Imaging: Digital Mammography, Breast MRI, and Ultrasound. These topics will be discussed by MSR radiologist Bobbi Ring M.D.

1 hour of category I CME credit will be awarded to participants.

Burton & Doyle is located on 661 Northern Blvd. in Great Neck. Appetizers and Sign-in will be at 6:30 pm with Dinner and Lecture starting at 7:00 p.m.

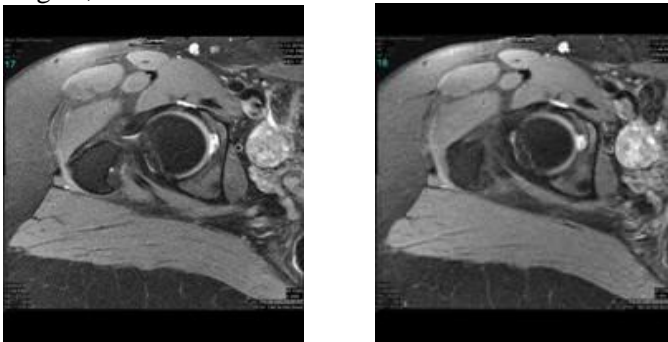
Please call Joanna, John or Steve at 718-428-1500 to RSVP by October 14.



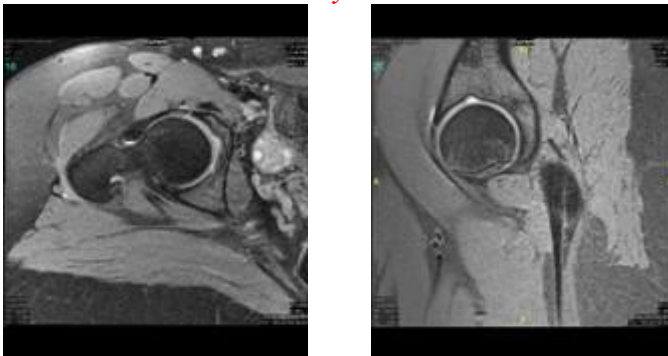
3 TESLA ORTHOPEDIC IMAGING

The Verio's impact on imaging of the musculoskeletal system has been dramatic. Because of the increase in signal to noise with the 3T MRI, a smaller field of view, thinner slices, and increased spatial resolution can be obtained. The higher signal to noise and increased spatial resolution at 3T is beneficial to help enhance the detection of tears of the articular cartilage of the labrum of the shoulder and hip, triangular fibrocartilage complex tears of the wrist, and to aid in the diagnosis and staging of various internal derangements of the knee and elbow. Offering higher spatial resolution, 3T MRI yields additional useful information in the study of smaller body parts and cartilage than examination obtained at 1.5T. The following images are examples of the type of detailed anatomy that can be obtained with Main Street Radiology's 3 Tesla MRI.

Clinical musculoskeletal studies have found 3T to be a distinct advantage. Anterior labral tears are well visualized, especially using proton-density fat-suppressed axial images. Superior labrum from anterior to posterior (SLAP) tears, which can be somewhat challenging to detect at lower field strengths, are well visualized.

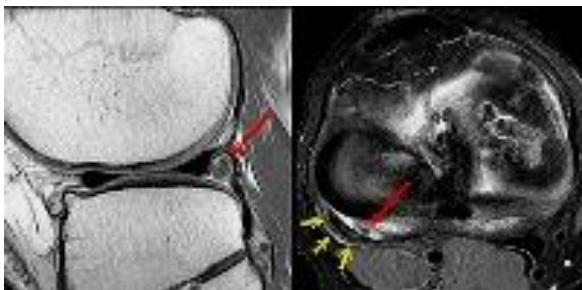


Detached Anterosuperior Labral Tear of the Right Hip with Small Paralabral Cyst Formation



The diagnosis of the detached labral tear can now be enhanced to evaluate the articular cartilage along the femoral head and acetabulum.

Anatomic variants, such as those associated with shoulder impingement, are displayed with increased clarity at high field. Routine knee imaging is also well performed at high field.

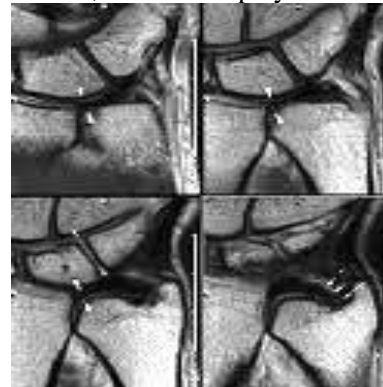


Knee Cartilage and Intra-Articular Bodies

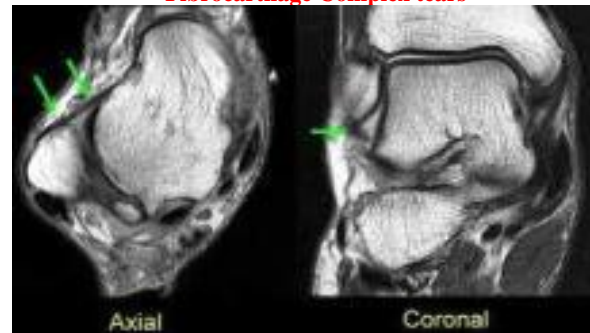
Meniscal tears are exquisitely detailed with increased resolution and contrast, and anterior cruciate ligament

abnormalities are well demonstrated. Evaluation of the articular cartilage and subchondral plate is significantly improved at 3T. Advanced phased-array coils show great promise in ankle imaging at 3T. Achilles tears are well delineated. Tendinopathy, ossicles, and other joint and soft-tissue pathology commonly evaluated at 1.5T are well evaluated at 3T.

Much interest is focused on 3T imaging of the wrist, which allows detailed views of the anatomy of the triangular fibrocartilage complex using proton-density fat-suppressed sequences and high-resolution GRE 3D FT imaging. High-resolution proton-density fat-suppressed sequences are excellent at detecting triangular fibrocartilage disc tears. Characteristic MR findings of impingement syndromes, such as ulnar impaction, and inflammatory arthropathy, such as rheumatoid arthritis, are also displayed in detail at high field.



Cartilage integrity at the wrist and location of Triangular Fibrocartilage Complex tears



Ligamentous detail at the ankle. Normal Anterior Talofibular ligament

The Verio enables Main Street Radiology to offer more complex imaging and work with a stunning new level of detail. Main Street Radiology can offer patients the best quality and most comfortable examinations due to the system's design.